

**REVISION JUNE 2009**

**BRACING FOR SCHEUERMANN'S KYPHOSIS**

B. Stephens Richards, MD  
Donald E. Katz, BS, CO  
Texas Scottish Rite Hospital for Children  
Dallas, Texas

**Introduction.** Bracing is indicated for Scheuermann's kyphosis when the deformity has been progressive, is painful or cosmetically unacceptable, and the patient is skeletally immature (a Risser  $\leq 2$ ). For Scheuermann's disease of the thoracic spine, the use of an orthosis is typically considered in kyphotic curves exceeding at least 60 degrees. Scheuermann's disease can also occur in the thoracolumbar or lumbar spine, with patients being considered for orthoses more typically being athletic males complaining of backache with less evident deformity<sup>1, 2</sup>. The goal of this treatment is not only to arrest progression but also to achieve permanent improvement in the kyphosis, as well as improve any evident pain in the process. This can result only if the anterior vertebral height is restored by application of hyperextension forces. Without actual reconstitution of the anterior vertebral height, the deformity will inevitably recur following the discontinuation of bracing.

**Brace types and Selection.** Three brace types have been described in the treatment of Scheuermann's kyphosis. At present, none of these utilize the emerging CAD-CAM technology that is becoming useful in the design of newer scoliosis braces. The Milwaukee brace has historically been the primary orthosis recommended for kyphosis located in the thoracic spine (Fig.'s 1, 2 and 3).

In general, if the apex of the deformity is located at or above the eighth thoracic vertebra, this brace is preferred. It has been shown to be an effective design in applying both a passive, anteriorly directed force at the midthoracic level of the spine working in combination with a patient's active response to extend the upper thoracic spine as a reaction to the presence of the neck ring. It is equally important to reduce lumbar lordosis in an effort to improve the overall

sagittal spinal alignment. Flexibility across the kyphotic segment is needed to treat a patient successfully with an orthosis. The Milwaukee brace is used less often today due patient concerns regarding an inability to conceal the orthosis effectively with clothing. The use of lower profile, thermoplastic orthoses are more commonly used in the treatment of thoracic kyphosis, and especially in patients with thoracolumbar or lumbar kyphosis.

The second brace type is the polypropylene thoracolumbosacral orthosis (TLSO) with an anterior sternal extension or padded anterior shoulder outriggers (Fig.'s 4-9).

This orthosis is typically indicated in the treatment of a deformity whose apex is located at or below the ninth thoracic vertebra. Like the Milwaukee orthosis, a thermoplastic TLSO also diminishes the lumbar lordosis, and has been shown to be an effective alternative to the Milwaukee brace in the treatment of thoracic Scheuermann's disease<sup>3,4</sup>. While the use of a TLSO in the treatment of Scheuermann's disease is generally more acceptable to the patient than a Milwaukee brace, compliance can still be a challenge due to some psychological manifestations associated with brace wear in general<sup>5</sup>. The third brace type is the polypropylene lumbosacral orthosis (LSO). It is designed to reduce the lumbar lordosis as much as possible, and by doing so, forces the patient to actively right himself out of the kyphotic thoracic posture. Though reported in one study to be effective, this brace design is used infrequently today<sup>6</sup>.

The initial use of brace treatment should be full-time, with the patient allowed to remove the brace 1-2 hours each day for exercise. Radiographs should be obtained in 3-4 month intervals to demonstrate improvement. With each visit, the posterior kyphosis pads should be adjusted by the orthotist to provide further correction. Ideally, to provide the best outcome, bracing should be continued until skeletal maturity. Realistically, this is difficult to achieve as the adolescent tends

to become less compliant with bracewear over time. Males may actually need to be encouraged to use the orthosis until later adolescence, when they become Risser 5. Weaning has been recommended although documentation of its effectiveness is lacking.

The two main North American studies reporting on the long-term results of bracewear have shown that the deformities are improved during the treatment period<sup>7, 8</sup>. However, following discontinuation of the brace, a loss of correction occurs. Larger deformities at the onset of treatment ( $>74^{\circ}$ ) show greater losses of correction following brace discontinuation. Correction achieved in smaller deformities is better maintained.

**Casts.** In the more severe deformities, cast treatment should be considered prior to use of an orthosis in order to achieve greater initial correction. This effect has been demonstrated using the methods of Ponte and Stagnara<sup>9, 10</sup>. To view a video presentation by Ponte called “Scheuermann’s Kyphosis: Non-operative treatment by plaster casts”, proceed to the SRS members’ only page <http://www.srs.org/professionals/members/> under Education and the surgery videos. Following use of several casts over a six-month period, patients are then fitted with a brace to maintain the correction. Once again, sufficient time in treatment is required in skeletally immature individuals in order to reconstitute the anterior vertebral height. These adolescents must have a strong desire for improvement through nonoperative management because compliance with a cast or brace is probably the primary factor for a successful outcome. For patients presenting at the post-pubertal stage with little growth remaining, casting or bracing cannot correct the anterior vertebral wedging and attempts to use either technique are probably not warranted.

**Biomechanics of orthotic stabilization.** Both the Milwaukee brace and the lower profile TLSO apply an anteriorly directed corrective force at and around the apex of the kyphotic segment, with simultaneous purchase of the pelvis and reduction of lumbar lordosis. The balance of both active and passive corrective forces, however, differs between the Milwaukee and TLSO designs.

The design of the Milwaukee brace is thoroughly described elsewhere in this manual of brace treatment and will only be summarized here. Consisting of a circumferential neck ring or lower profile superstructure design, (Figures 1-3) the corrective three points of pressure are accomplished by a combination of both passive and active forces. The most inferior point of pressure comes from the thermoplastic pelvic portion of the orthosis, also referred to as the pelvic girdle. The importance of an accurately fitted pelvic girdle cannot be overemphasized. It provides the inferior base of support upon which all other components of the brace design depend. The pelvic girdle should fulfill three primary criteria: 1) It should decrease lumbar lordosis; 2) It should be shaped to lock onto the pelvis without impinging on the iliac crests, and 3) It should have a snug fitting and appropriately contoured waist groove to prevent superior or inferior migration of the orthosis<sup>11</sup>.

The second point of pressure, which is the primary corrective force for the kyphotic deformity, comes from corrective pads exerting an anteriorly directed force at and just inferior to the apical vertebrae of the curve. These pads are mounted on the posterior, paraspinal uprights of the brace's superstructure. Made of a dense polyethylene foam, they are shaped and sized for an even distribution of corrective force.

Proximally, the third point of pressure (directed posteriorly) depends on an active response by the patient rather than on passive forces. The neck ring design invokes a noxious, posteriorly directed stimulus superior to the apex of the thoracic kyphosis. Also known as a “kinesthetic reminder,” this superior third point of pressure relies on the patient to actively pull away, thus further reducing the size of the kyphosis while in the brace. In theory, the more traditional, circumferential neck ring is used for higher thoracic curves (e.g. T6 and above), while the lower profile neck ring designs are more suited to mid-thoracic curves (e.g. apices of T7 or T8). Little evidence exists, however, to substantiate the idea of a the patient providing the active correction elicited either by the standard ring design in relation to the neck or by the superior sternal pad in relation to the upper thorax. The success that the Milwaukee brace design does suggest, however anecdotally, that some level of active correction takes place. Without it, in-brace reduction of thoracic kyphosis would be negligible, since no posteriorly directed force can be exerted at the cervical (throat) level, and very little at the level of the sternal notch.

The thoracolumbosacral orthosis (TLSO) is more typically used in the treatment of low thoracic, thoracolumbar or lumbar kyphosis. Relying more on passive correction of the kyphotic deformity rather than the active correction of a patient’s posture by kinesthetic reminder, the deformity must be low enough in the spine to allow the exertion of a posteriorly directed corrective force that is adequately superior to the apex of the curve. This thermoplastic TLSO is typically custom molded to the patient, utilizing a casting technique which passively decreases the kyphotic deformity. A mold is often taken with the patient lying in the supine position, with the hips flexed to reduce lumbar lordosis, while lying over a bolster at the apex of the kyphosis or positioned in a similar fashion using a casting frame<sup>3,4</sup>. Fabrication of the inferior portion of the

orthosis is similar to that described in the making of a pelvic girdle for a Milwaukee brace. Since a metal superstructure is not typically employed in this brace design, pads are mounted on the interior wall of the posterior aspect of the brace at, and below, the apex of the kyphosis. Superior to the curve's apex, however, an effort is made to apply a posteriorly directed, padded force upon the Manubrium, and often, the delto-pectoral grooves. The delto-pectoral extensions employ a more dynamic aspect (reduction of shoulder protraction through a kinesthetic response) toward correcting the kyphotic curve (Fig. 10a-e).

Regardless of the various techniques that can be employed to apply a corrective force superior to the apex of the kyphotic curve, care must be taken to provide adequate relief to the lower anterior chest wall to enable maximal in-brace correction. This is usually achieved by fashioning a large window between the abdominal apron and the sternal extension of the orthosis (Fig. 5).

The lumbosacral orthosis (LSO) that aggressively decreases lumbar lordosis has also been reported to be an effective method for correcting a flexible kyphosis. The corrective action of the brace is a result of the patient having to actively right himself out of a kyphotic posture in response to the in-brace reduction of lumbar lordosis. This requires a flexible spine, kyphosis less than 70 degrees, a normal neurovestibular axis, and the absence of hip flexion contractures. Its use is uncommon.

**Brace Adjustability.** Increasing the amount of corrective force on a kyphotic spine in these braces can be achieved in multiple ways. For the Milwaukee brace, the orthotist can utilize any one, or a combination, of the following adjustments:

- 1) Thicken the pads mounted to the paraspinal bars;
- 2) Contour the paraspinal bars into more of an anti-kyphotic posture;
- 3) Raise the anterior superstructure, causing the patient to increase the amount of effort required to dynamically decrease the kyphotic posture. Note: great care must be taken so as to not exceed the amount of corrective posture a patient is capable of maintaining, especially while seated.
- 4) The neck ring can be translated more posteriorly, typically by lowering the posterior and raising the anterior superstructure, respectively, in relation to the pelvic girdle. This action necessitates a dynamic postural correction by the patient;
- 5) The amount of lumbar lordosis can be decreased by contouring the relationship between the inferior portion of the paraspinal uprights and the anterior superstructure, respectively.

With the exception of option #1, each of these adjustments requires a qualified orthotist experienced in the fabrication and fitting of a Milwaukee Brace.

For the TLSO, the corrective forces can be adjusted by adding to or reducing the thickness of the pads utilized in the passive correction of the deformity. Further clinical correction of the kyphosis may result but requires a void, or opening in the anterior chest wall of the orthosis (mentioned earlier), thus giving the thorax "some place to go."

With regard to the patient's growth, both the Milwaukee brace and the TLSO have some flexibility. The posterior-opening design of the pelvic portion will accommodate a change in girth. Adjustments to accommodate changes in the patient's trunk height are much easier with the Milwaukee brace. Its aluminum superstructure can be periodically lengthened to meet the need.

In summary, achieving success with brace management of Scheuermann's kyphosis requires constant attention of both the orthopaedic surgeon and orthotist. Continuous regular



adjustments to the orthosis are needed to maximize in-brace correction of the deformity. The orthotist must dedicate the time and energy necessary to master the various techniques available, while the orthopaedist must also understand the principles behind the design options that exist to both prescribe an appropriate system, and offer guidance to the orthotist, patient and care givers throughout the treatment process.

## References

1. Blumenthal SL, Roach J, Herring JA: Lumbar Scheuermann's. A clinical series and classification. *Spine* 1987;12:929-932.
2. Greene TL, Hensinger RN, Hunter LY: Back pain and vertebral changes simulating Scheuermann's disease. *J Pediatr Orthop* 1985;5:1-7.
3. Gomez M, Flanagan P, Gavin T: An alternative bracing approach to Scheuermann's disease: a case study. *J Prosth Orthot* 2002;14:109-114.
4. Riddle EC, Bowen JR, Shah SA, Moran EF, Lawall H, Jr.: The duPont kyphosis brace for the treatment of adolescent Scheuermann kyphosis. *J South Orthop Assoc* 2003;12:135-140.
5. Korovessis P, Zacharatos S, Koureas G, Megas P: Comparative multifactorial analysis of the effects of idiopathic adolescent scoliosis and Scheuermann kyphosis on the self-perceived health status of adolescents treated with brace. *Eur Spine J* 2007;16:537-546.
6. Gutowski WT, Renshaw TS: Orthotic results in adolescent kyphosis. *Spine* 1988;13:485-489.
7. Montgomery SP, Erwin WE: Scheuermann's kyphosis--long-term results of Milwaukee braces treatment. *Spine* 1981;6:5-8.
8. Sachs B, Bradford D, Winter R, Lonstein J, Moe J, Willson S: Scheuermann kyphosis. Follow-up of Milwaukee-brace treatment. *J Bone Joint Surg Am* 1987;69:50-57.
9. Ponte A, Gebbia F, Eliseo F: Nonoperative treatment of adolescent hyperkyphosis: a 30-year experience in over 3000 treated patients. *Orthop Trans* 1990;14:766.

10. Stagnara P: Cyphoses thoraciques regulieres pathologiques, in Gaggi A (ed) *Modern Trends in Orthopaedics*, 1982.
11. Carlson JM: *A Thoraco-Lumbo-Sacral-Orthosis for Idiopathic Scoliosis -- Part II*. St. Paul, 1981.

## Figure Legends

Fig 1: Posterior View - Milwaukee Brace

Fig 2: Lateral View - Milwaukee Brace

Fig 3: Anterior View - Milwaukee Brace

Fig. 4: Posterior View

Fig 5: Anterior View

Fig 6: Lateral View

Fig 7: Adolescent with thoracic kyphosis. Note excessive lumbar lordosis

Fig 8: In TLSO

Fig 9: In-brace.

Fig 10a-e: Adolescent with thoracic Scheuermann's kyphosis: LSO with delto-pectoral extensions.

Figure 1

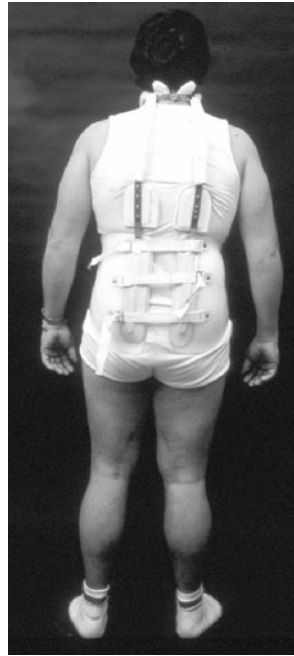


Figure 2



Figure 3

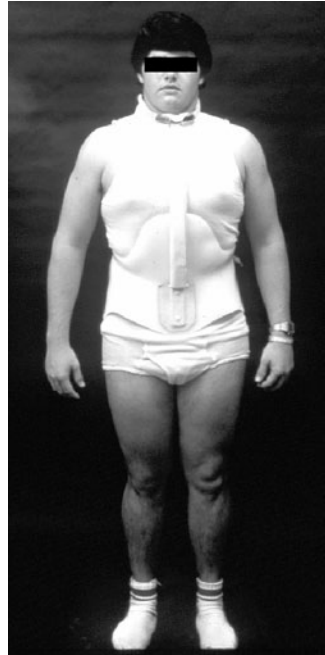

Figure 4

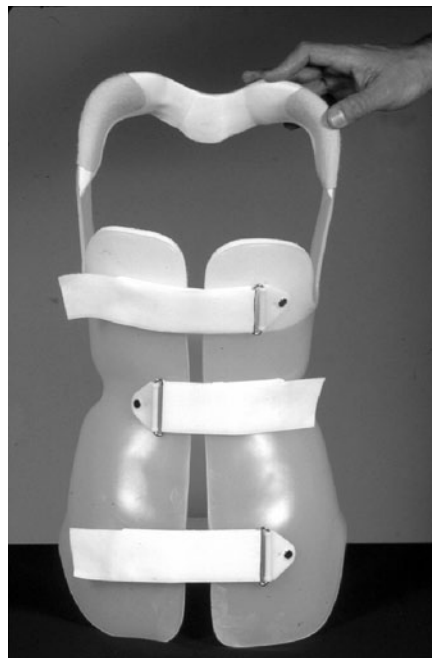

Figure 5

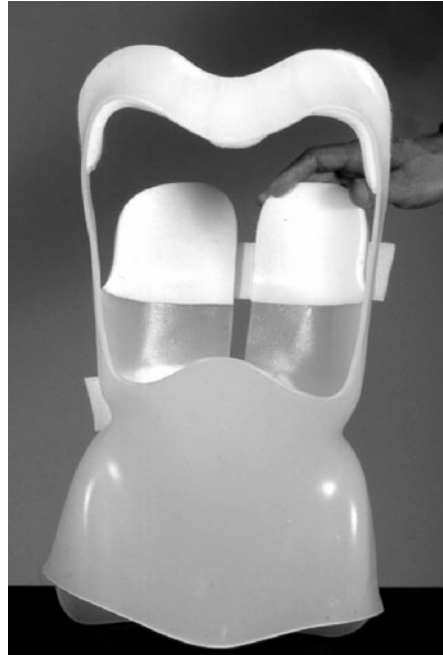

Figure 6

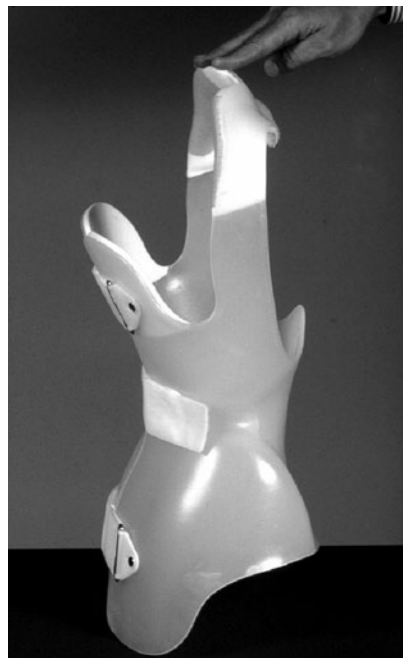

Figure 7



Figure 8





Figure 9



Figure 10a

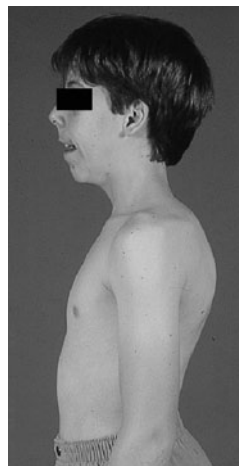

Figure 10b

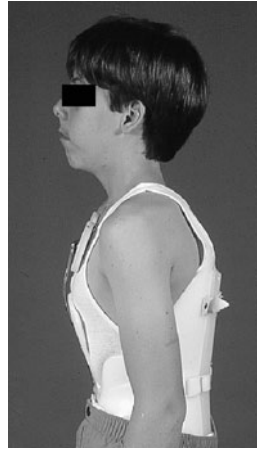

Figure 10c

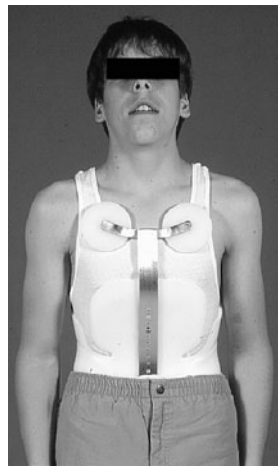


Figure 10d

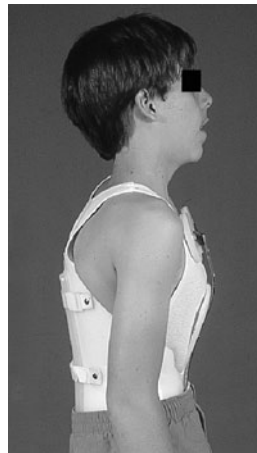


Figure 10e

