

***The
Providence
Scoliosis
System***

Manual

Charles d'Amato M.D. F.R.C.S. (C)

Barry McCoy MEd. C.P.O.

Table of Contents

Introduction -----	page 2
Clinical Experience -----	page 5
Force Application -----	page 8
Clinical Evaluation/ X-Ray Interpretation -----	page 14
Measurement / Casting Board -----	page 17
Measurement Form -----	page 18
Casting Procedure -----	page 19
Fitting the Providence Orthosis -----	page 20
Pressure Testing -----	page 22
Patient Instructions -----	page 25
Providence Brace Carbon Fiber -----	page 26
References -----	page 27

Introduction

The Providence Brace was developed when it was observed that significant correction of scoliotic curves could be achieved using an acrylic frame to apply direct corrective forces to the patient. The frame (see below) was originally developed to demonstrate supine spinal flexibility for pre-operative radiographic planning. The frame works by the application of controlled, direct, lateral and rotational forces on the trunk to move the spine toward the midline or beyond the midline. It does not bend the spine as with the Charleston bending brace.

The brace is fabricated of polypropylene plastic from measurements or a plaster impression. The patient is placed on a polycarbonate measurement and casting board. The board has a grid of holes on its surface for placement of the bolsters to apply corrective forces and stabilization to the spine with reference the patient's midline. They enable one to accurately apply forces to the lateral surfaces of the patient's body. Information from a standing radiograph of the patient's spine serves as a guide for the placement of the stabilizing and corrective bolsters used in the casting or measurement process.

Originally, the patient is removed from the board and wrapped in a standing plaster jacket, returned to the board and the bolsters are returned to the determined settings. The dried plaster jacket is then removed and used as a female mold to make a male plug on which the brace is custom made. At the outset, all of our braces were fitted in this manner. Over the past six years, cast molds were scanned into a CAD/CAM computer enabling the brace fabrication to be done with measurements alone in 95% of cases.

Delrin® bolsters or stabilizing blocks are used at the end points of curves and pressure blocks are located at the apices of the curves to be treated. Control of rotation is accomplished

in two different ways. In the lumbar spine the pressure pad is located between the iliac crest and the twelfth rib. When pressure is applied this pad creates a posterior lateral pressure as it is tightened due to a wedging of the pad against the surface of the board. De-rotation in the thoracic section of the brace is accomplished on the CAD/CAM model. The thoracic section is separated from the lumbar section. Then the thoracic portion is rotated a specific amount and rejoined to the lumbar section of the model.

The amount of corrective force used is monitored with the use of pressure sensitive film (Fuji, inc. ®). The average lumbar pressure measured inside the brace is 7.4lbs./sq. in. in the lumbar spine and 5.4 lbs./sq. in. in the thoracic spine. Pressure measurements are helpful in avoiding excessive pressures that can lead to intolerance of the brace and the development of skin problems. Pressure testing gives the orthotist a guideline so he/she doesn't harm the patient. When the patient outgrows the brace, it becomes tight circumferentially but there is a decrease in pressure at the apex of the curve or curves. Consequently, pressure readings serve to evaluate the ongoing effectiveness of the brace as the patient grows.

A computer program selects a CAD-CAM model based upon the measurements from the polycarbonate board. The model is further modified to match the patient's measurements. It is then milled out in a computerized milling machine.

Clinical Experience

Study Design. A prospective study was conducted of 102 consecutive female patients with adolescent idiopathic scoliosis. These patients with Risser 0,1 and 2 met the criteria for inclusion and were treated only with the Providence Brace.

Objectives. The first objective is to report our findings with a hyper-corrective nighttime brace and to evaluate the results with respect to risk factors for progression. Secondly, the study compares results with expectations from the natural history as reported by Lonstein and Carlson and the multi-center prospective study of Nachemson et al. in girls

Summary and Background: Compliance with full time brace treatment for adolescent idiopathic scoliosis has been a problem. Since the introduction of the Milwaukee brace, alternatives such as low profile braces, reduced wearing schedules, and nighttime only bracing have been tried. However, many factors influence the success or failure besides compliance. These include in-brace correction, brace design, and orthotists skills. This is the first report of the results of treatment with a new nighttime brace that is made with CAD/CAM technology that can achieve higher initial in-brace corrections than other reported methods.

.Methods. Results were analyzed with respect to curve size, curve pattern, maturity, and level of the primary curve apex. Both compliant and non-compliant patients were included in the analysis. A univariate analysis was done on those factors thought to influence success with bracing using the Pearson chi square test.

Results. The average initial in-brace correction with a supine radiograph was 96% for major curves and 98% for secondary curves. Seventy-five patients (74%) did not progress over five

degrees and twenty-seven patients (26%) progressed six degrees or more or went on to surgery. Only twenty-nine percent of patients, Risser 0 or 1 progressed, and seventeen percent of patients Risser 2 progressed. Risser 3 and 4 patients were excluded from the study. The risk of progression anticipated by the natural history data of Lonstien et al., which included all curve patterns, was 68% and 23% respectively. Seventy-six percent of patients with curve apices between T 8 and L 1 were successful using the Providence Brace. This is compared with 74% success rate in the prospective SRS study of patients wearing a TLSO for sixteen hours per day with curves between T 8 and L1. Sixty-three percent of thoracic curves and 65% of double curves were successful. Ninety-four percent of lumbar curves and 93% of thoraco-lumbar curves were successful.

Conclusion. Excellent initial in brace correction of adolescent idiopathic scoliosis was observed with this computer designed and manufactured recumbent brace. Risser 0 or 1 patients with high apex curves cephalad to T-8 (n=28) had a success rate of 61% compared with a success rate of 77% (n=56) if the apex was at or below T-9.

Compared with the natural history and the prospective study data of Nachemson et al, the Providence Brace is effective in preventing progression of adolescent idiopathic scoliosis for curves under 35 degrees and for low apex curves over 35 degrees. Our experience with patients who had high apex curves over 35 degrees (n=8) is too small to validate its effectiveness for larger curves.

In conclusion, nighttime only bracing with the Providence Brace has been effective in preventing curve progression in 74 % of our patients with adolescent idiopathic scoliosis particularly for curves under thirty-five degrees. In our series of patients, the Providence

brace provides greater than 75% initial in brace correction in 88% of major curves with an average initial in-brace correction of 96%. More flexible thoraco-lumbar and lumbar curves were often over corrected on the initial in-brace supine radiograph. The ability to standardize the fitting and manufacture of this brace, using computer aided design and manufacturing technology may assist orthotists in providing a consistent product. This study has few subjects with curves over 35 and therefore it is recommended with caution as the sole primary treatment for larger curves, especially if the major curve apex is T-8 or higher. **Spine 2001; 26:2006-2012**

Force Application

The goal in the application of lateral force in the Providence Scoliosis System is to use the centerline as a reference and bring the apexes of the scoliotic curve to that line or beyond. This involves the use of three point pressure systems and void areas that are located opposite these pressures. We have found through pressure testing that it is important to keep the shell of the orthosis continuous. When holes are cut in the shell of an orthosis the amount of pressure exerted by the orthosis drops significantly. Therefore the use of void areas is a must to maintain sufficient pressure within a orthosis. (Fig.1)

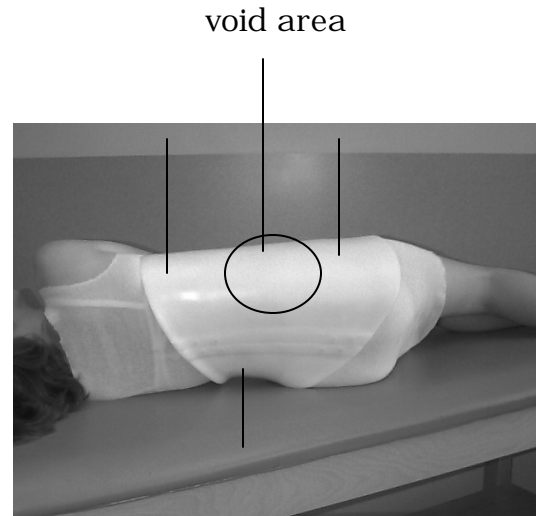


Figure 1

The three point pressure systems are overlapping in the case of double curves.

Derotational Forces

Segmental derotation of the spine is accomplished in different ways depending on the area of the spine. In the lumbar spine, the area in which a derotational force can be applied is very small. Segmental derotational is produced by the angle of the lumbar pad itself in this area. (Fig 2)

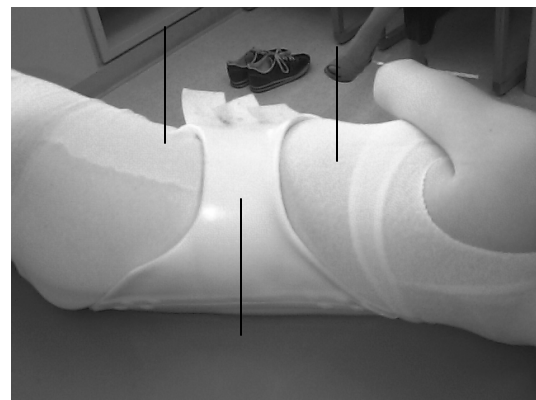


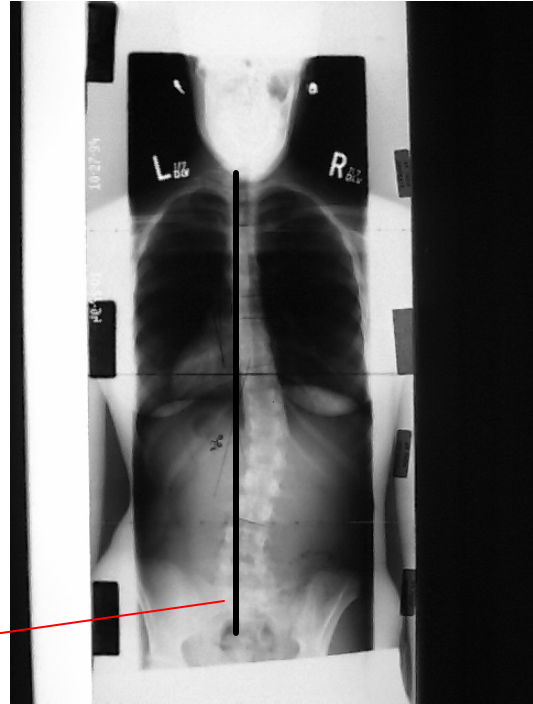
Figure 2

Reference Lines:

A straight line drawn between the middle of the sacrum and the spinous process of C-7 has proven to be a better aid in X-Ray evaluation. Since the patient is positioned on the measuring board with C-7 and the middle of the sacrum on the midline of the board, it makes sense to evaluate the X-Ray in the same fashion.

All Providence braces have a lumbar pad. It is placed where and apical pressure pad is located or it is the end point of a three point pressure system in a thoracic curve. In light of this, many times it is obvious where the lumbar pad should go, sometimes it is more difficult. A key vertebra to look at is L-2 in determining where the lumbar pad should be placed. If the majority of the body of L-2 falls to the right of the centerline then the pad is placed on the right, if it falls to the left then it is placed on the left side of the

brace. This is usually only a problem when treating curve with low thoracic apexes.



The following pages are exercises to help you become familiar with how forces are applied and how different curves are described using the Providence Scoliosis System.

In the thoracic area of the spine, the ribs act as a long lever arm with which to derotate the vertebrae. As a result the entire shell of the brace is rotated in this area.

Taking Advantage of the Recumbent Position

There are certain things that can be done in the supine and prone position that can't be done with a full time or day brace. They are:

1. Trimming the side of the brace opposite the trochanteric pad completely away. This allows constant pressure to be maintained on the lumbar spine, even if the ML of the patient's hips widens with growth.

2. Rotating the thoracic portion of the orthosis to gain better rotational control.

3. Elevating the patient's shoulder in order to have a higher stabilizing pad on the upper thoracic spine. We have found that patients can sleep with the shoulder slightly elevated allowing us to apply a higher counter force than what is possible in full time or day

bracing. This allows us to treat curves with apexes as high as T-6.

4. Locating the thoracic pressure pad one vertebral level higher than the apex, as seen on the standing X-Ray. This is

possible due to straightening of the curve and extension of the ribs in the supine position with the brace on.

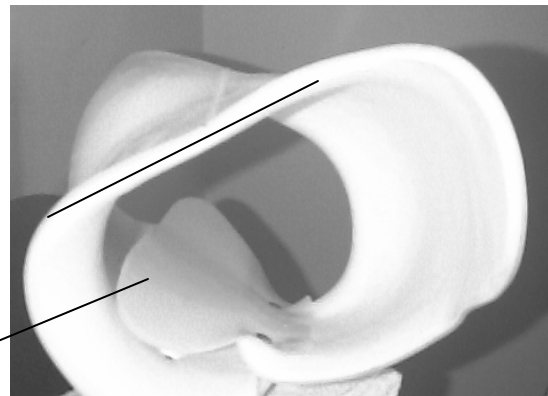


Figure 3

Examples of force vectors are shown on the following pages.

Curve Description

Thoracic Ⓡ L

Lumbar R Ⓛ

Thoracic Apex T-8

Lumbar Apex L-2

Curve type Double Curve

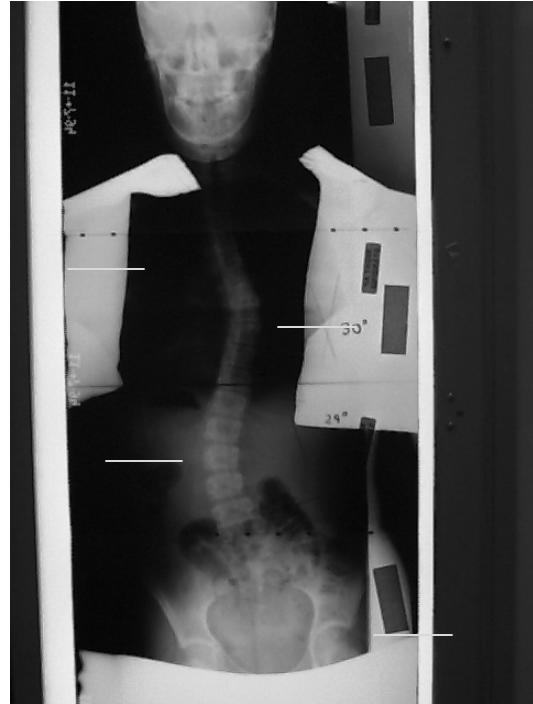


Figure 4

Curve Description

Thoracic Ⓡ L

Lumbar Ⓡ L

Thoracic Apex

Lumbar Apex L-1

Curve type Right Thoracolumbar

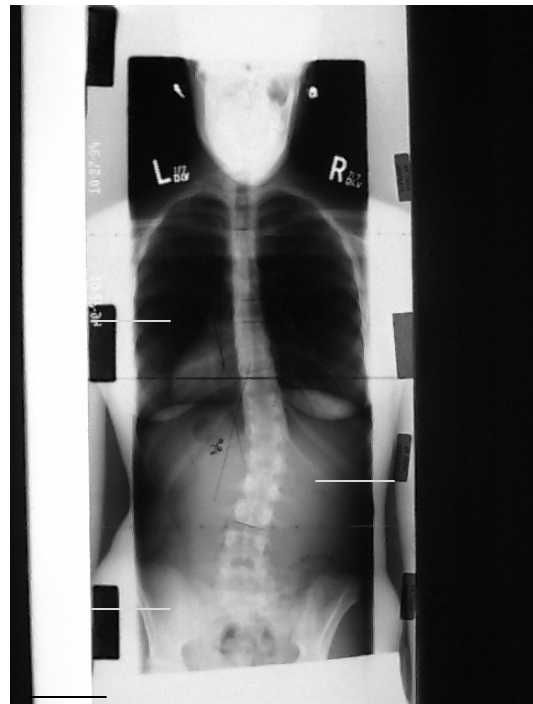

Figure 5

Curve Description

Thoracic (R) L

Lumbar R L

Thoracic Apex T-9

Lumbar Apex _____

Curve type Right Thoracic

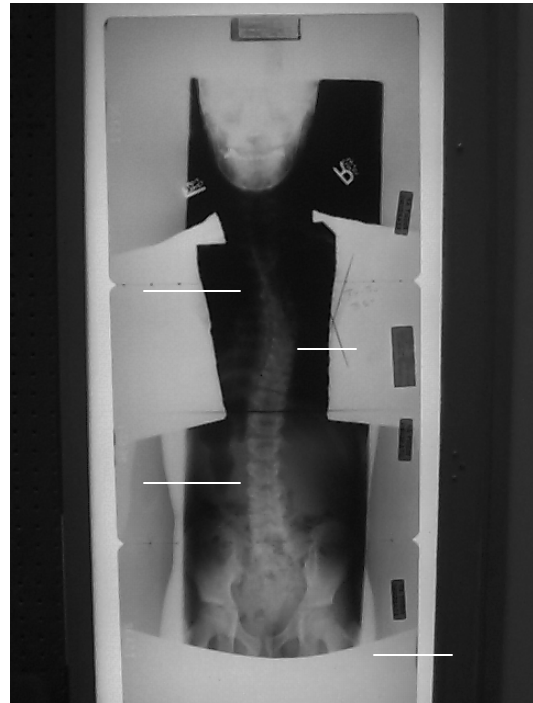


Figure 6

Curve Description

Thoracic R L

Lumbar R (L)

Thoracic Apex _____

Lumbar Apex L-2

Curve type Left Lumbar

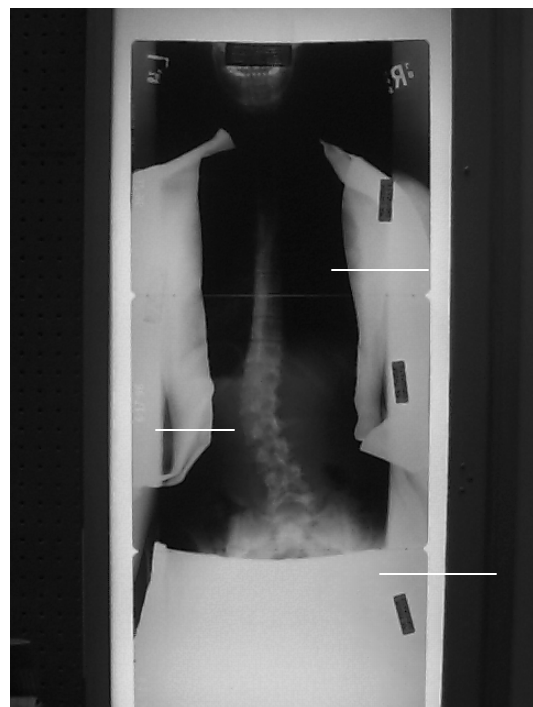


Figure 7

Curve Description

Thoracic (R) (L)

Lumbar R L

Thoracic Apex T-4 and T-11

Lumbar Apex _____

Curve type Double Thoracic

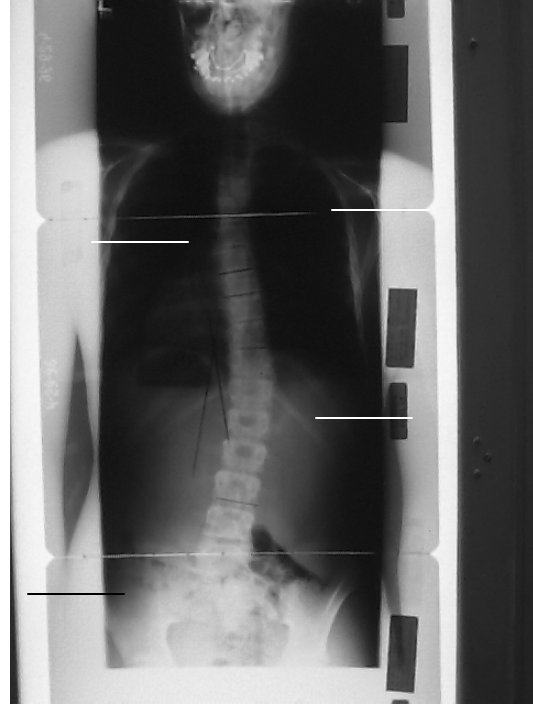


Figure 8

Curve Description

Thoracic R L

Lumbar R (L)

Thoracic Apex _____

Lumbar Apex L-2

Curve type Lumbar

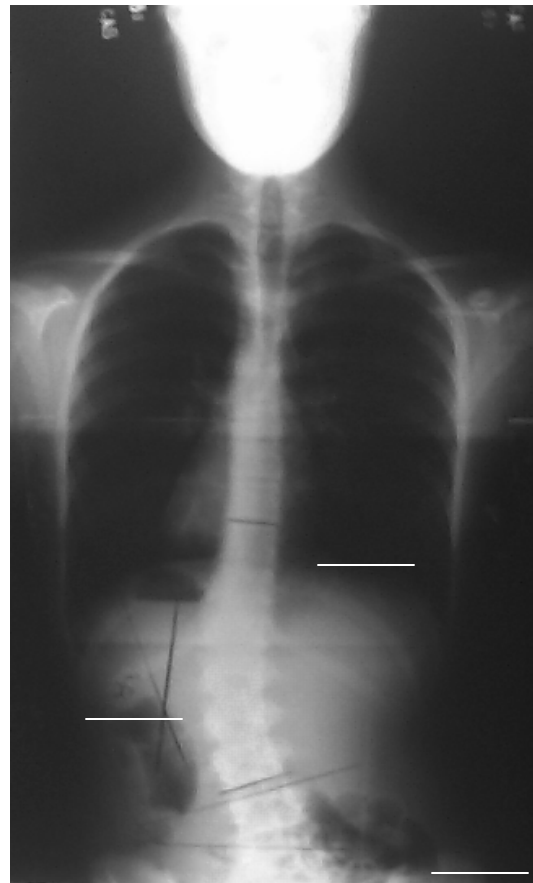


Figure 9

Clinical Evaluation

The purpose of clinical evaluation is to transfer the radiographic information learned from the x-ray to the patient's body.

After the patient is clothed in cotton stockinet, it is important to view the patient both standing, and in the Adams' (forward bending) position. Markings are placed on the stockinet at the approximate levels where the apices of the curves are located.

In the lumbar spine this area is localized and rests between the iliac crest and the twelfth rib.

In the thoracic spine an effort should be made to locate the apical vertebrae on the spinal column. The ribs descend from the vertebra on a downward angle in the standing position. In the supine position the ribs tend to elevate as the spine extends. This means that pad placement will usually be higher than what is usually expected in a daytime brace.

It is also important to keep in mind that when a double curve is straightened the spine will tend to elongate. For this reason the pad placement for the apex of the thoracic curve will be higher than traditionally expected. Marks are then placed on the stockinet to

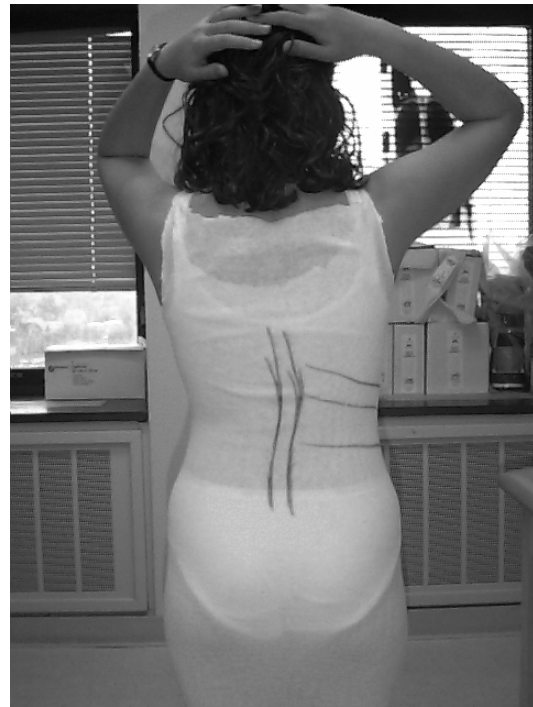

Figure 10

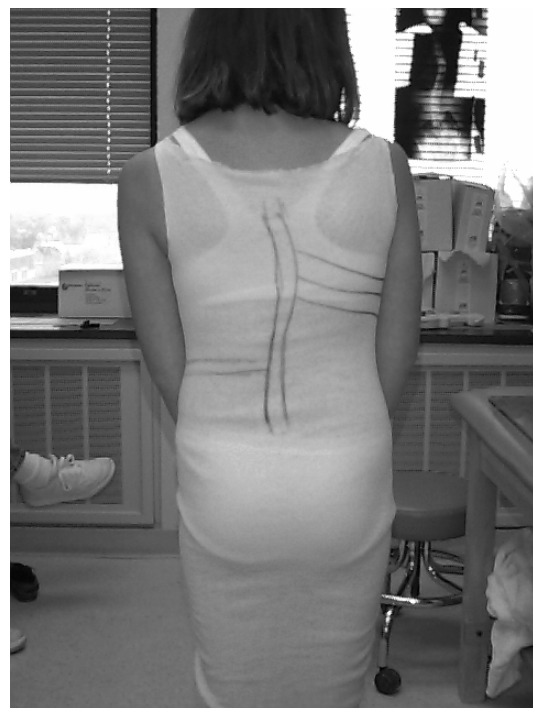

Figure 11

Pad Placement

Step 1.

The lumbar pad is placed in the zero row on the board, either on the right or left side of the body.

All Providence Scoliosis System orthoses have a lumbar pad. They may be shaped differently according to the curve. There are two reasons for this.

1. It is either the end point of a thoracic curve or at the apex of a lumbar curve.

2. It keeps the orthosis located on the patients body at the proper height. This is important in treating thoracic curves especially those with high apexes.

Step 2.

Stabilizing pads are then added to the lateral sides of the patient to hold the patient on the centerline of the board. These are placed according to the type of curve that is to be braced. In this case, the pad placement would be for a left lumbar right thoracic curve.

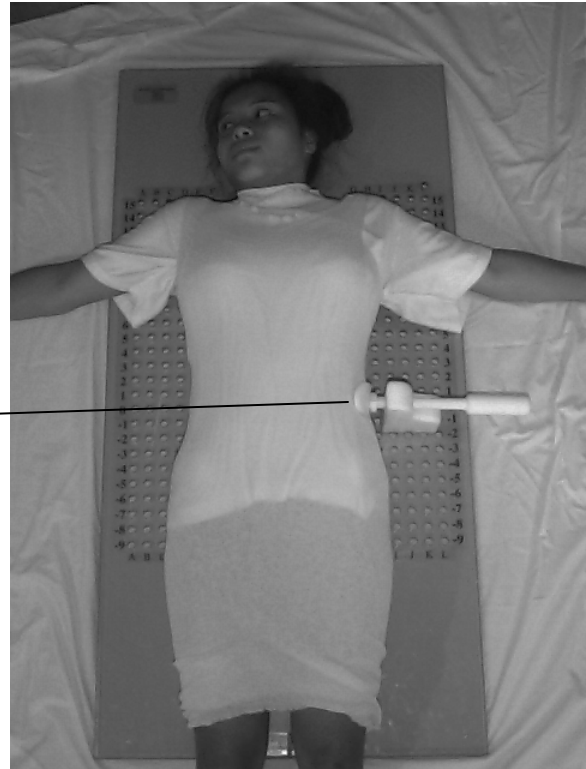

Figure 15

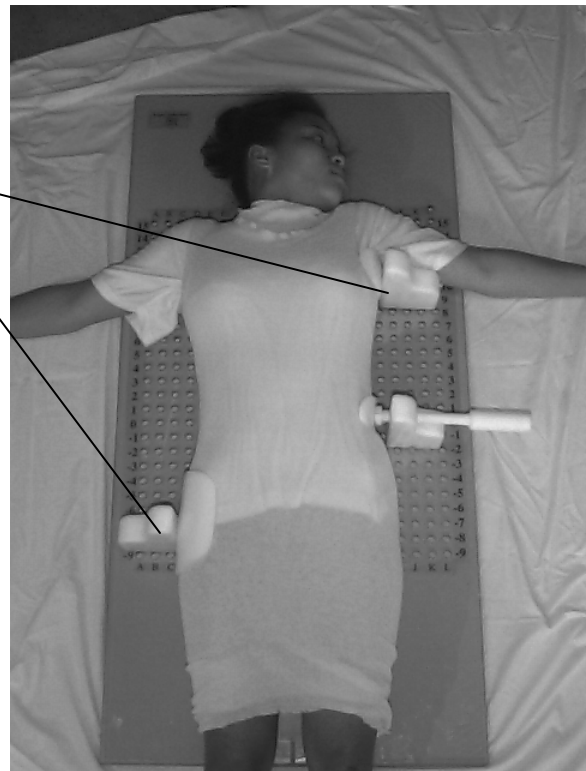


Figure 16

Step 3.

Remaining pressure pads are then positioned and tightened.

Pressure pads are tightened to patient tolerance, some ranges are important to keep in mind.

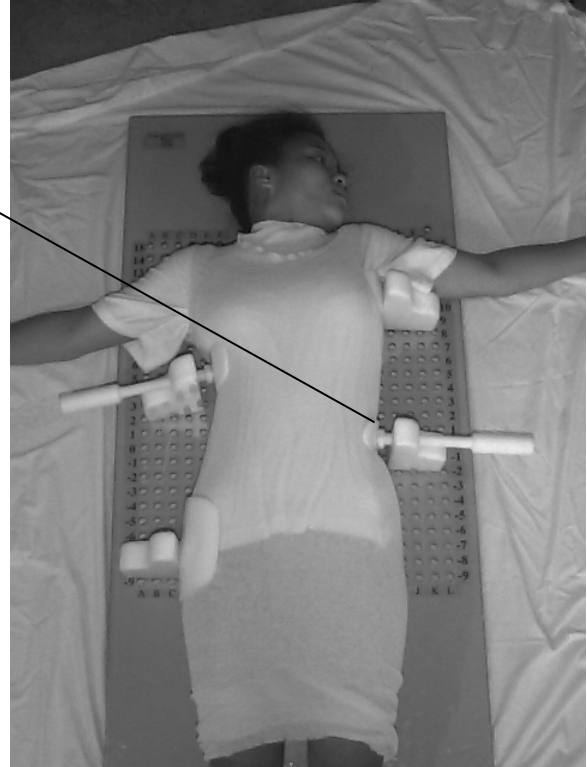


Figure 17

Lumbar compression:

25mm to 50mm or 1" to 2" is common and can be tolerated by most patients. This depends on:

1. the amount of soft tissue
2. the flexibility of the spine
3. the patients tolerance to pressure

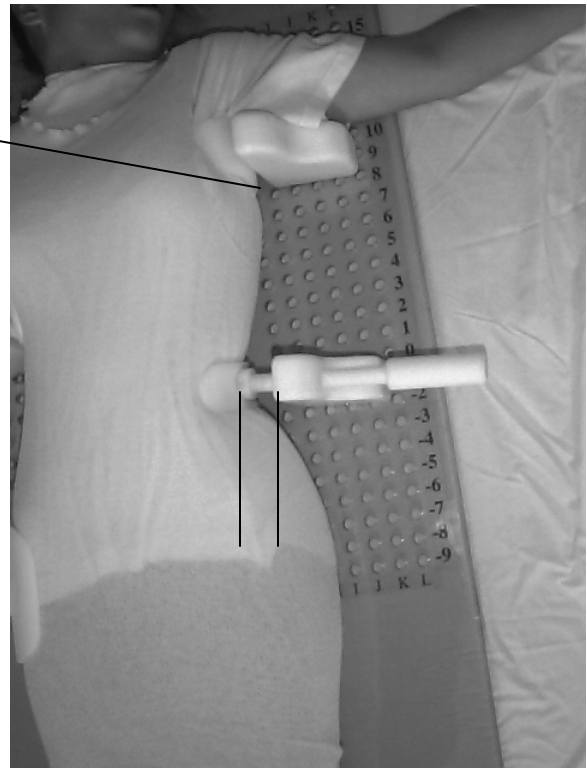


Figure 18

Thoracic Compression:

Between 20mm and 40mm (3/4" to 1 1/4") is the usual amount of compression. In the thoracic area of the spine, pressure is generally less than the lumbar spine. This is dependent on:

1. Any chest wall abnormalities
2. The tolerance of the patient
3. Flexibility of the spine

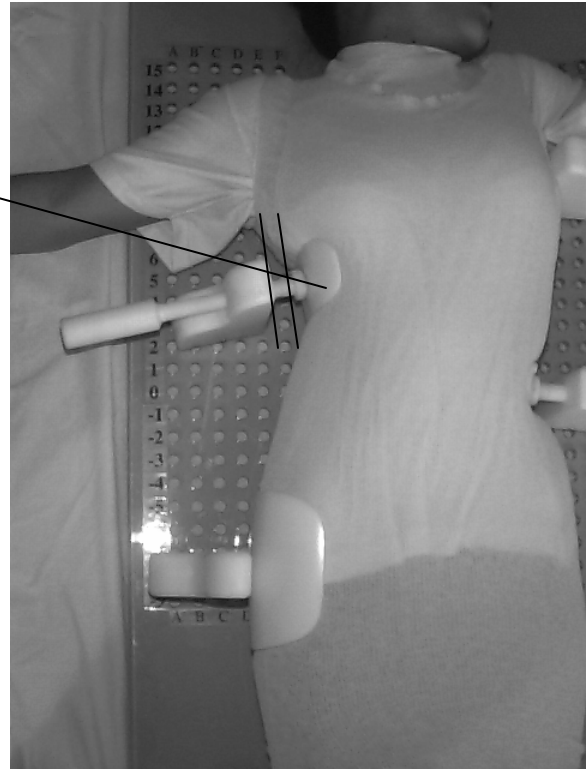


Figure 19

Recording Measurements

1. For all pads record the hole position in which the pin is located.

2. For pressure pads, also record the amount of compression. This is measured from the vertical surface of the block to the fitting that holds the pressure pad.




Figure 20

Providence Scoliosis System

Measurement Form

Name _____ Date _____

Age _____ Sex _____ Height _____ Weight _____

Curve Description

Thoracic curve	R	L
Lumbar curve	R	L
Thoracic apex	T- _____	
Lumbar apex	L- _____	

Curve type _____

1. Thoracic
 2. Lumbar
 3. Thoracolumbar
 4. Double

ABCDE F	HEAD	GHIJKL
15		15
14		14
13		13
12		12
11		11
10		10
9		9
8		8
7		7
6		6
4		4
3		3
2		2
1		1
0		0
-1		-1
-2		-2
-3		-3
-4		-4
-5		-5
-6		-6
-7		-7
-8		-8
-9		-9
ABCDE F	FEET	GHIJKL



CIR



AP

AXILLA _____

XYPHOID _____

WAIST _____

ASIS _____

TROCH _____

PAD PLACEMENT

STABILIZING PADS	COLUMN	ROW	
AXILLA PAD	_____	_____	
TROCHANTER PAD	_____	_____	
PRESSURE PADS	COLUMN	ROW	DISTANCE
LUMBAR PAD	_____	_____	_____
THORACIC PAD	_____	_____	_____

Casting Procedure

Not every patient should be measured for an orthosis on the measurement frame. Therefore, it is important to know how to cast using the Providence Scoliosis System.

Who should be casted:

1. Patients with a hip circumference larger than 95 cm
2. Patients with a hip circumference smaller than 55 cm
3. Patients with a curve larger than 45 degrees
4. Any patient with an abnormal body shape.

Our mold inventory used in the CAD/CAM program, although extensive, was taken primarily from adolescent idiopathic scoliotic patients. Orthoses for other types of scoliosis i.e. neuromuscular, juvenile, congenital etc. should be casted.

Items needed:

Cotton stockinet
8" plaster bandage
cut-off strip
cast knife
polyethylene plastic bag

Step 1

Position the patient on the board as described earlier on pages 7 through 10. After proper positioning of stabilizing and pressure pads is achieved, record hole positions and remove patient from board.

Step 2

With patient clothed in stockinet, take a standing cast with the patient holding the cut-off strip anteriorly. The average patient requires 4 rolls of eight-inch plaster to cover the torso. Start at the trochanter and circumferentially wrap the plaster up to the axilla. As you approach the axilla, instruct the patient to put his or her hands on top of their head. Wrap the plastic bag around the plaster wrap to protect the board and pads.

Step 3

Reposition the patient on the board. Place stabilizing and pressure pads that have been removed and tighten before plaster sets.

Step 4

After the plaster has set, cut the cast anteriorly along the cut-off strip. While holding the cast open have the patient sit-up and move toward the bottom of the cast. Close the cast and staple shut.

If done properly, an impression of the center line should be in the middle of the cast posteriorly.

Fitting the Providence Orthosis

The initial fitting is accomplished by holding the brace open while the patient lies down into the orthosis.

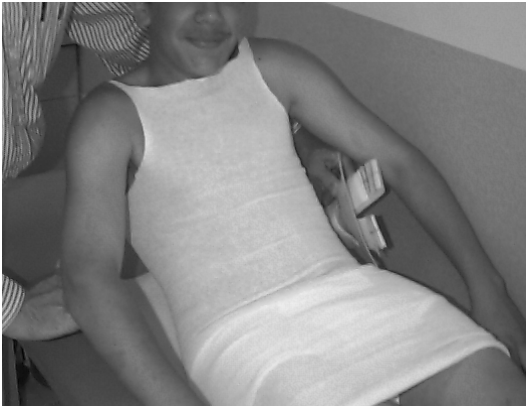

Figure 21

Make sure that the lumbar pad of the orthosis is located opposite the umbilicus. This locates the orthosis at the proper vertical position on the patient's body.

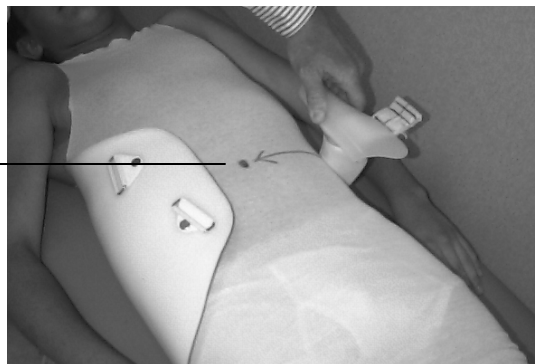


Figure 2

Check to make sure the lumbar pad fits in between the lower border of the ribs and the top of the iliac crest.

It may be necessary to trim some portion of the lumbar pad to contour the orthosis around the entire length of the iliac crest.

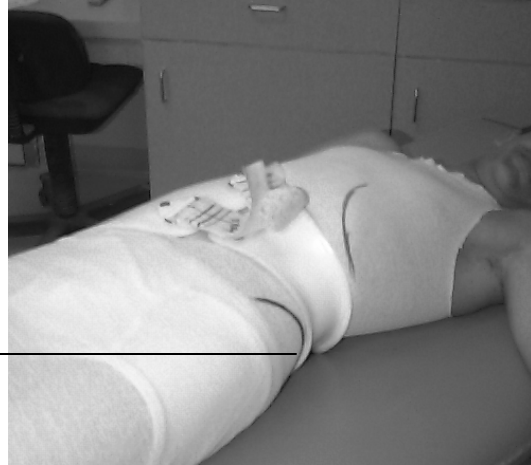

Figure 23

Make sure the axilla extension is the proper height. If it is too long it will cause downward pressure on the top of the iliac crest and can cause numbness along the lateral surface of the leg. This is irritation of the lateral cutaneous femoral nerve. This can also be caused by a lumbar pad if it is not contoured properly over the iliac crest.

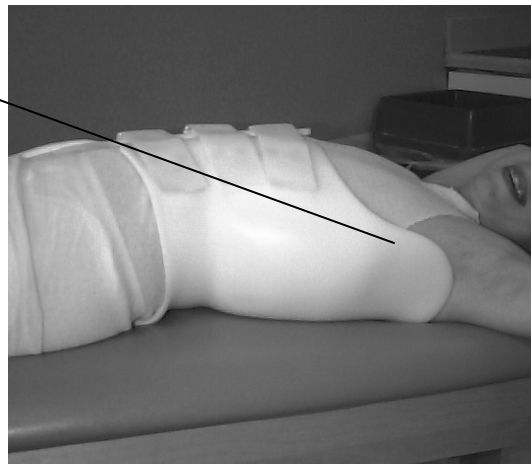


Figure 24

Pressure Testing

After the initial fitting is completed, remove the orthosis. Place pressure sensitive film inside the orthosis where the apical vertebrae are located. For consistent results it is important that pressure readings are taken at the same location in the orthosis each time.

Place the film along the inside radius of the lumbar pad about one inch from the bottom flare, running anteriorly.

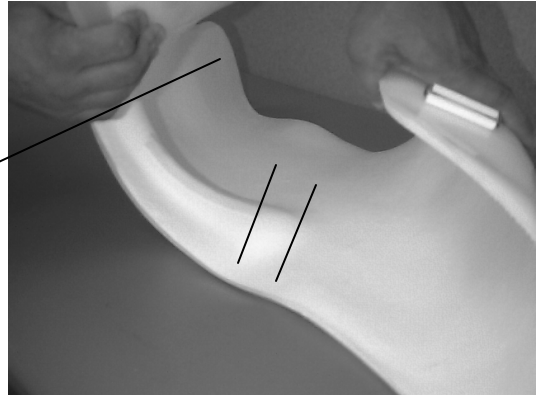


Figure 24

On the thoracic pad, locate the film approximately 1 inch below the flare of the brace where the pad is thickest.



Figure 25

Place the prescale mat over each area where the film is placed and lie the patient back into the orthosis as described above.

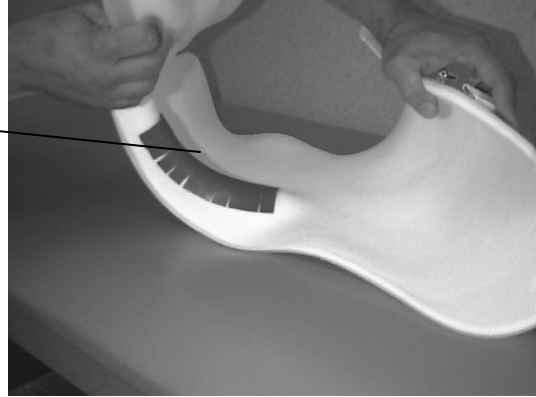


Figure 26

Reading the pressure is done with the Providence Scoliosis System goniometer.

The size of the dots are the important thing to keep in mind, not the color of the ink. Place the goniometer over the pressure strip and read the corresponding pressure.




Figure 27

Tighten the orthosis until there is less than a 25mm or 1" opening between the two front pieces of plastic. This should feel very tight to most patients. Draw a line on the strap with a marker.

Loosen the orthosis to establish a 50mm or 2" opening and draw a second line on the Velcro strap. Remove the orthosis and read the pressure sensitive film. What you have measured is the greatest pressure the orthosis can generate on the apical vertebrae. In the lumbar spine pressures range between 4 PSI and 14 PSI, in the thoracic spine between 4PSI and 10 PSI.

The goal in the beginning is to sleep in the orthosis. This is done with very low pressure readings. Once the patient is able to sleep throughout the night, tightening the orthosis to within a range of pressures is necessary. The average pressure reading in the lumbar spine is 7.4 PSI. In the thoracic spine it is 5.5 PSI. ***Although these pressures are averages, caution should be exercised considering the individual patient, their body type, and their tolerance to pressure.***

It is helpful to keep the pressure sensitive film in the chart for future comparison.

Suggested Orthotic Protocol

After the patient receives the orthosis and initial pressure readings are taken, a two-week follow-up visit is scheduled. At this visit a pressure test is taken at the loose setting used during the break-in period. If that pressure reading falls within the average range of pressures, the patient is instructed to wear the orthosis at that setting for the next three months.

At each additional three-month check-up a pressure test is taken to assure that apical vertebral pressure is within normal limits. This usually requires the orthosis to be tightened gradually.

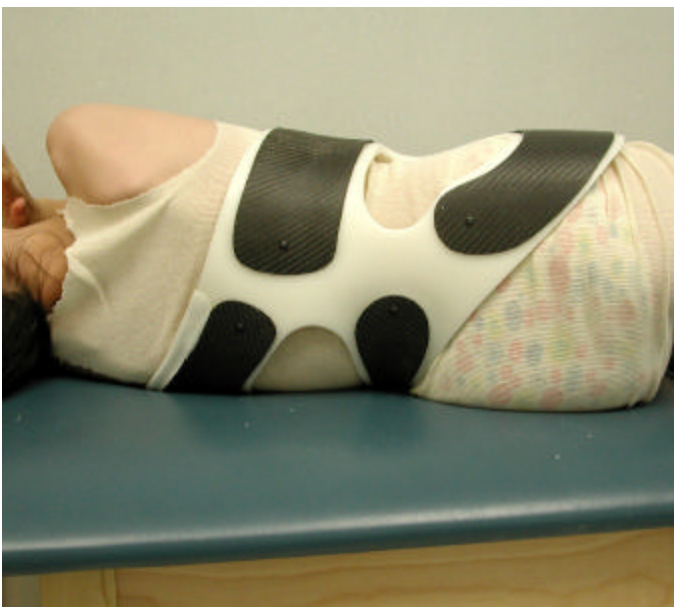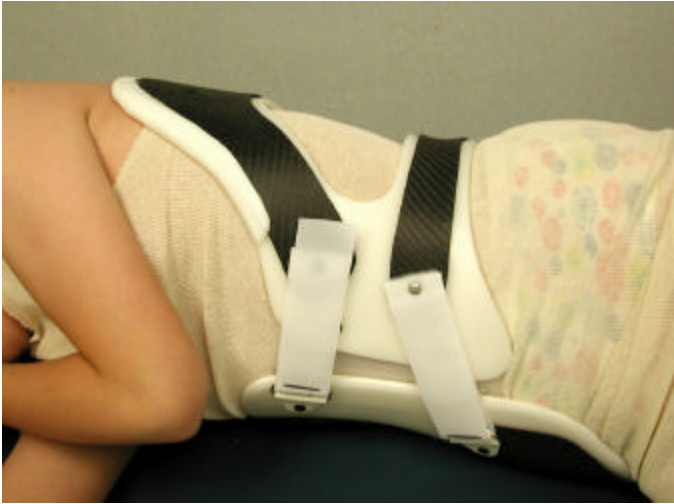Instructions for Wearing a Scoliosis brace

1. Always wear a clean T-shirt under the brace. It should be long enough to extend below the bottom of the brace. The T-shirt should be slim fitting, not baggy. Loose fitting shirts worn under the brace can cause skin problems. Dyed or colored T-shirts are not recommended.
2. The brace can be washed inside and out with soap and water to keep it clean. This is especially important in warm weather.
3. Keep the brace tightened to the line drawn on the strap as instructed by your orthotist.
4. Use rubbing alcohol on the areas of your skin where the brace applies pressure, this will help prevent skin problems.
5. The break in period is usually about one week. Put the brace on lying down in bed. For the first few nights you will probably sleep only a few hours in the brace before waking. When you wake up, remove the brace and sleep the rest of the night without the brace on. Repeat this procedure every night. You will find that you will be able to sleep for a longer time in the brace each night. If it takes any longer than two weeks to sleep all night in the brace, please contact this office.
6. It is important to have periodic pressure tests performed by your orthotist to ensure that the brace is still effectively treating your child's scoliosis. Return appointments should be scheduled at regular intervals.

Carbon Fiber Reinforced*

Providence Brace CFR*

The use of advanced composite materials has led to stronger and lighter devices in the field of orthotics and prosthetics. We have found that applying carbon fiber reinforcements provides the patient with a more comfortable and effective brace. These additions keep the plastic from “creeping” or curling in while also maintaining the shape of the pressure and stabilizing pads. It also allows us to cut out the void areas making the brace cooler and more comfortable. All of the edges that contact the patient’s skin are plastic while additional stiffness is provided in critical areas.



Reference

1. ALLINGTON, N.J. and BOWEN, J.R.: Adolescent idiopathic scoliosis: treatment with the Wilmington brace. A comparison of full-time and part-time use [see comments]. *J Bone Joint Surg Am*, **78**: 1056-1062, 1996.
2. BASSETT, G.S.; BUNNELL, W.P.; and MACEWEN, G.D.: Treatment of idiopathic scoliosis with the Wilmington brace. Results in patients with a twenty to thirty-nine-degree curve. *J Bone Joint Surg [Am]*, **68**: 602-605, 1986.
3. BUNNELL, W.P.: The natural history of idiopathic scoliosis before skeletal maturity. *Spine*, **11**: 773-776, 1986.
4. CARR, W.A.; MOE, J.H.; WINTER, R.B.; and LONSTEIN, J.E.: Treatment of idiopathic scoliosis in the Milwaukee brace. *J Bone Joint Surg [Am]*, **62**: 599-612, 1980.
5. CLIMENT, J.M. and SANCHEZ, J.: Impact of the type of brace on the quality of life of Adolescents with Spine Deformities. *Spine*, **24**: 1903-1908, 1999.
6. COCHRAN, T. and NACHEMSON, A.: Long-term anatomic and functional changes in patients with adolescent idiopathic scoliosis treated with the Milwaukee brace. *Spine*, **10**: 127-133, 1985.
7. DICKSON, R.A. and WEINSTEIN SL: *JBJS[Br]*, **81 - B**: 193-198, 1999.(Abstract)
8. D'AMATO, C.R., GRIGGS, S. and McCOY, B.: Nighttime Bracing With the Providence Brace in Adolescent Girls With Idiopathic Scoliosis. *Spine* 26: 2006-2012.
9. EMANS, J.B.; KAELIN, A.; BANCEL, P.; HALL, J.E.; and MILLER, M.E.: The Boston bracing system for idiopathic scoliosis. Follow-up results in 295 patients. *Spine*, **11**: 792-801, 1986.
10. ERICKSON EH: The syndrome of identity diffusion in adolescents and young adults. In *Discussions in Child Development*, pp. 133-168. Edited by Tanner JM and Inhelder B. London, Tavistock Publ, 2000.
11. GREEN, N.E.: Part-time bracing of adolescent idiopathic scoliosis. *J Bone Joint Surg [Am]*, **68**: 738-742, 1986.
12. HOUGHTON GR; MCINERNEY, A.; and TEW, A.: Brace compliance in adolescent idiopathic scoliosis. *JBJS[Br]*, **69B**: 8521997.

13. KATZ, D.E.; RICHARDS, B.S.; BROWNE, R.H.; and HERRING, J.A.: A comparison between the Boston brace and the Charleston bending brace in adolescent idiopathic scoliosis. *Spine*, **22**: 1302-1312, 1997.
14. LONSTEIN, J.E. and CARLSON, J.M.: The prediction of Curve Progression in Untreated Idiopathic Scoliosis During Growth. *The Journal of Bone and Joint Surgery*, **66-A**: 1061-1071, 1984.
15. LONSTEIN, J.E. and WINTER, R.B.: The Milwaukee brace for the treatment of adolescent idiopathic scoliosis. A review of one thousand and twenty patients. *J Bone Joint Surg Am*, **76**: 1207-1221, 1994.
16. MCCOLLOUGH, N.C.; SCHULTZ, M.; JAVECH, N.; and LATTA, L.: Miami TLSO in the management of scoliosis: preliminary results in 100 cases. *J Pediatr Orthop*, **1**: 141-152, 1981.
17. NACHEMSON, A.L. and PETERSON, L.E.: Effectiveness of treatment with a brace in girls who have adolescent idiopathic scoliosis. A prospective, controlled study based on data from the Brace Study of the Scoliosis Research Society [see comments]. *J Bone Joint Surg Am*, **77**: 815-822, 1995.
18. PETERSON, L.E. and NACHEMSON, A.L.: Prediction of progression of the curve in girls who have adolescent idiopathic scoliosis of moderate severity. Logistic regression analysis based on data from The Brace Study of the Scoliosis Research Society. *J Bone Joint Surg Am*, **77**: 823-827, 1995.
19. PRICE, C.T.; SCOTT, D.S.; REED, F.E.J.; and RIDDICK, M.F.: Nighttime bracing for adolescent idiopathic scoliosis with the Charleston bending brace. Preliminary report. *Spine*, **15**: 1294-1299, 1990.
20. PRICE, C.T.; SCOTT, D.S.; REED, F.R.J.; SPROUL, J.T.; and RIDDICK, M.F.: Nighttime bracing for adolescent idiopathic scoliosis with the Charleston Bending Brace: long-term follow-up. *J Pediatr Orthop*, **17**: 703-707, 1997.
21. TERMINOLOGY COMMITTEE OF THE SCOLIOSIS RESEARCH SOCIETY: A Glossary of Terms. *Spine*, **1**: 57-8, 1976.
22. WILEY, J.; THOMPSON, J.; MITCHEL, T.; SMITH, B.; and BANTA, J.: Effectiveness of the Boston Brace in Treatment of Large Curves in Adolescent Idiopathic Scoliosis. *Spine*, **25 (!18)**: 2326-2332, 2000.